

VANDETANIB (CAPRELSA): AN ANTI-CANCER DRUG THAT IS USED FOR THE TREATMENT OF MEDULLARY THYROID CANCER (MTC)

DILIPKUMAR PAL^{1,*}, TANMOY DE²

¹Department of Pharmaceutical Sciences, Guru Ghasidash Vishwavidyalaya (A Central University), Koni, Bilaspur -495 009, C.G., ²School of Pharmaceutical Sciences, IFTM University, Lodhipur, Rajput, Moradabad, UP, 244 001, India. Email: drdilip71@gmail.com

Received: 10 May 2013, Revised and Accepted: 26 Jun 2013

ABSTRACT

Vandetanib (Caprelsa) is an anti-cancer drug that is used for the treatment of medullary thyroid cancer (MTC). It is an oral small-molecule tyrosine kinase inhibitor (TKI) that selectively targets the rearranged during transfection receptor (RET), vascular endothelial growth factor receptor (VEGFR2-3), and epidermal growth factor receptor (EGFR). It has been approved by US FDA in April 2011 for treatment of late-stage (metastatic) medullary thyroid cancer in adult patients who are ineligible for surgery. In phase III clinical trials of vandetanib, 331 patients with advanced or metastatic medullary thyroid cancer were allocated to receive 300 mg of vandetanib. It is a double-blind placebo controlled study and the patients received vandetanib (n=231) or placebo (n=100) in ratio of 2:1. Vandetanib improved progression-free survival compared with placebo [HR, 0.46; 95% confidence interval (CI), 0.31-0.69; P < 0.001]. The most common reported adverse reactions (greater than 20%) are diarrhea, rash, acne, nausea, hypertension, headache, fatigue, decreased appetite, abdominal pain, hypocalcemia, hypoglycemia, and increased alanine transaminase (ALT), QTc prolongation.

Keywords: Vandetanib, Medullary thyroid cancer, RET, VEGFR

INTRODUCTION

The most common symptom of thyroid cancer is nodule [1, 2] in the thyroid region of the neck. Thyroids contain small nodules in adults but typically fewer than 5% of these nodules are found to be malignant. Other various sign and symptoms of thyroid cancer are enlargement of lymph nodes, pain in the anterior region of the neck and changes in voice due to an involvement of the recurrent laryngeal nerve. Thyroid cancer is usually found in a euthyroid patient, but symptoms of hyperthyroidism or hypothyroidism may be associated with a large or metastatic well-differentiated tumor [3, 4].

Medullary thyroid cancer (MTC) is originated from the parafollicular cells (C cells). MTC is a form of thyroid carcinoma and it produces the hormone calcitonin [5], a hormone that helps control the amount of calcium in blood. Medullary tumors are the third most common of all thyroid cancers. Medullary thyroid carcinoma (MTC) accounts for about 4% of thyroid cancers. It is estimated that 25% of MTC is genetic in nature and it is caused by a mutation in the RET proto-oncogene [6]. Sometimes this cancer can travelled to lymph nodes,

the lungs, or liver even before a thyroid nodule is discovered. There are two types of MTC such as sporadic MTC and familial MTC. Sporadic MTC [7] does not run in families and it occurs mostly in older adults. It is not inherited. But familial MTC run in families and it occurs mostly during childhood or early adulthood and can spread early. It is inherited. Diarrhea is the major clinical symptom of MTC and occasionally a patient will have flushing episodes. In MTC, the flushing, diarrhea, and itching (pruritis) are all caused by elevated levels of calcitonin gene products (calcitonin or calcitonin gene-related peptide).

In United States, the rate of thyroid cancer has been steadily increasing over the past several decades. It has been found that the thyroid cancer rates more than double in the United States from 1975 to 2007. In 2003-2007, the age adjusted incidence of thyroid cancer 15.2 per 100,000 in females compared to 5.2 per 100,000 males [8, 9, 10]. Data from the Hawai'i Tumor Registry of the National Cancer Institute's Surveillance, the age-adjusted incidence among women was highest in Filipinas (27.7 per 100,000) and lowest in Japanese (9.1 per 100,000) from the year between 2000-2005 [11, 12, 13].

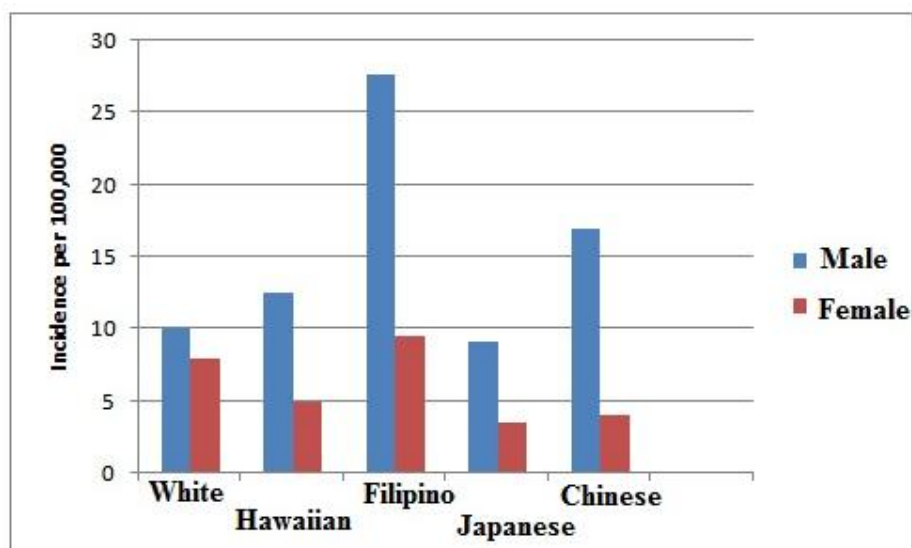


Fig. 1: Invasive thyroid cancer incidence, Hawaii 2000-2005 (Age-adjusted to United States 2000 Standard) [11]

Table 1: Risk factors for thyroid cancer [14-16]

Factors affecting thyroid cancer	Description
Age and sex	Thyroid cancer often seems to occur more in case of females than in males (about 3 times more in females than in men). Thyroid cancer can occur at any age, but the risk peaks earlier for women (who are most often in their 40s or 50s (when diagnosed) than for men (who are usually in their 60s or 70s).
A diet low in iodine	Follicular thyroid cancers are more common in areas of the world where people's diets are low in iodine. In the United States, most people get enough iodine in their diet because it is available in the table salt and other foods. A diet low in iodine may also increase the risk of papillary cancer if the person also is exposed to radioactivity.
Radiation	Exposure to radiation is an important risk factor for thyroid cancer. Sources of such radiation include certain medical treatments and emission of radiation from power plant accidents or from nuclear weapons. If any person had a head or neck radiation treatment in his childhood then it is a risk factor for thyroid cancer, now the risk depends on how much radiation is given and the age of the child. In general, the risk increases with larger doses and with younger age at treatment. Radiation therapy in childhood for some cancers such as lymphoma, Wilms tumor, and neuroblastoma also increases the risk. Generally thyroid cancers that develop after radiation therapy are not severe than other thyroid cancers.
Hereditary conditions and family history	Several inherited conditions have been linked to different types of thyroid cancer, according to the family history. But still it is seen that most of the people who develop thyroid cancer do not have an inherited condition or a family history of the disease.

Vandetanib [17] has been approved by US FDA in April 2011 for treatment of late-stage (metastatic) medullary thyroid cancer in adult patients who are ineligible for surgery. It is being marketed under the trade name Caprelsa since August 2011. It is an anti-cancer drug that is used for the treatment of certain tumours of the thyroid gland. Mechanistically, it acts as a kinase inhibitor of a number of cell receptors, mainly the vascular endothelial growth factor receptor (VEGFR), the epidermal growth factor receptor (EGFR), and the RET-tyrosine kinase. Astra Zeneca is a British-Swedish multinational pharmaceutical and biologics company headquartered in London, United Kingdom and vandetanib is developed by this company [18]. It is administered orally and the tablets are available in two dosage strengths, 100 mg and 300 mg, containing 100 mg and 300 mg of vandetanib, respectively. The chemical name of vandetanib is N-(4-bromo-2-fluorophenyl)-6-methoxy-7-[(1-methyl-piperidine-4-yl)methoxy]quinazolin-4-amine. The molecular formula is $C_{22}H_{24}BrFN_4O_2$. It has molecular weight of 475.26. Vandetanib exhibits pH dependent solubility with increased solubility at lower pH. Vandetanib is practically insoluble in water with a value of 0.008 mg/ml at 25°C (77°F) [19].

Fig. 2: Structure of Vandetanib [20]

Mechanism of action: Vandetanib

Vascular endothelial growth factor (VEGFR) [21] is made by cells and it stimulates new blood vessels (microvessels) formation. It has a critical role in the tumor growth. The inhibition of VEGFR signaling inhibits growth of new tumor vessels by preventing endothelial cell proliferation and migration. Epidermal growth factor receptor (EGFR) [20] is a protein and it is present on the surface of cells. It is important in a variety of processes associated with tumor growth. Rearranged during transfection (RET) [23] is an abbreviation for "rearranged during transfection" as the DNA sequence of this gene was originally found to be rearranged within a 3T3 fibroblast cell line. The RET is localized to chromosome 10 and contains 21 exons. RET can give rise to the hereditary cancer syndrome.

Vandetanib is an oral small-molecule tyrosine kinase inhibitor (TKI) [24] that selectively targets the vascular endothelial growth factor receptor (VEGFR) [25], rearranged during transfection receptor (RET), VEGF receptor, epidermal growth factor receptor (EGFR), members of the Src family (a family of non-receptor tyrosine kinases that includes nine members: Src, Yes, Fyn, and Fgr, forming the SrcA subfamily, Lck, Hck, Blk, and Lyn in the SrcB subfamily, and Frk in its own subfamily) of tyrosine kinase, protein tyrosine kinase 6. It also inhibits endothelial cell migration, proliferation, survival and new blood vessel formation in *in vitro* models of angiogenesis. In addition, vandetanib inhibits epidermal growth factor (EGF)-stimulated receptor tyrosine kinase phosphorylation in tumor cells and endothelial cells and VEGF-stimulated tyrosine kinase phosphorylation in endothelial cells [26].

Fig. 3: Schematic mechanism of Vandetanib [24-26]

Pharmacokinetic study

Pharmacokinetic study of vandetanib was performed in 331 patients with MTC. The patients were given 300 mg daily dose orally. The absorption of vandetanib is slow and peak plasma concentration typically achieved at a median of 6 hours, range 4-10 hours, after dosing. Vandetanib has a mean volume distribution of approximately 7450L. It has tendency to binds to human serum albumin and α -1-acid-glycoprotein with in vitro protein binding being approximately 90%. N-desmethylvandetanib, vandetanib N-oxide and glucuronide conjugate of vandetanib are three metabolites detected in plasma, urine and feces. CYP P450 3A4 enzyme is responsible for metabolism of vandetanib which is converted into N-desmethylvandetanib. Approximately 44% and 25% vandetanib was recovered in feces, urine over 21 days. Excretion of the dose was

slow. The mean clearance of vandetanib is approximately 13.2 L/h and medium plasma half life is 19 days [27, 28].

Clinical trials

In phase III clinical trials of vandetanib, 331 patients with advanced or metastatic medullary thyroid cancer were allocated to receive 300 mg of vandetanib. It is a double-blind placebo controlled study and the patients received vandetanib (n=231) or placebo (n=100) in ratio of 2:1. The primary end point was PFS (Progression-free survival). The median progression-free survival was 19.3 in the placebo group and had not been reached at data cut-off in the vandetanib group. Significant prolongation of PFS was observed for patients receiving vandetanib compared with placebo (hazard ratio [HR], 0.46; 95% CI: 0.31–0.69; P, 0.001).

Fig. 4: Clinical trial profile [20, 29]

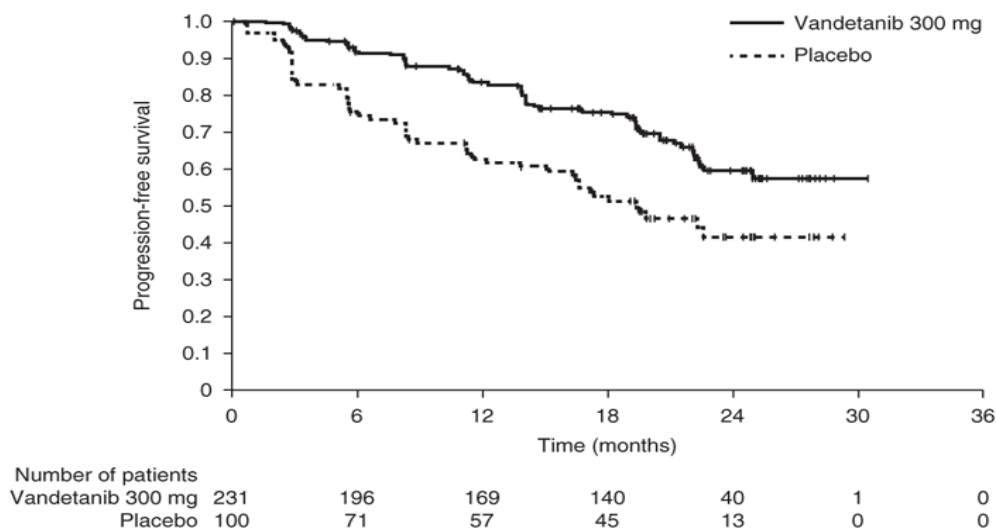


Fig. 5: Kaplan–Meier Curves for PFS from the Phase III ZETA Study Data in Patients with MTC [30]

Adverse reactions of vandetanib

The most common reported adverse reactions [20] (greater than 20%) are diarrhea, rash, acne, nausea, hypertension, headache, fatigue, decreased appetite, abdominal pain, hypocalcemia, hypoglycemia, and increased ALT.

Cardiovascular

Cardiovascular side effects have included hypertension (33%; grade 3 to 4: 9%), QT interval prolongation (14%; grade 3 to 4: 8%), cardiac failure, and arrhythmias.

Skin Reactions and Stevens - Johnson syndrome

Dermatologic side effects have included rash (53%; grade 3 to 4: 5%), dermatitis acneiform/acne (35%; grade 3 to 4: 1%), dry skin (15%), photosensitivity reaction (13%; grade 3 to 4: 2%), pruritus (11%; grade 3 to 4: 1%), nail abnormalities (9%), alopecia (8%), folliculitis, blue-gray macules, and hand-foot skin reaction [30, 31].

Interstitial Lung Disease

Interstitial Lung Disease (ILD) or pneumonitis has been observed with vandetanib and deaths have been reported. Consider a

diagnosis of ILD in patients presenting with non-specific respiratory signs and symptoms such as hypoxia, pleural effusion, cough, or dyspnea, and in whom infectious, neoplastic, and other causes have been excluded by means of appropriate investigations. Advise patients to report promptly any new or worsening respiratory symptoms.

Hemorrhage

Hematologic side effects have included bleeding events, decreased white blood cells (19%), decreased hemoglobin (13%), decreased neutrophils (10%), and decreased platelets (9%).

Diarrhea

Diarrhea was observed in patients who received vandetanib. Routine anti-diarrheal agents are recommended. Diarrhea may cause electrolyte imbalances. Since QT prolongation is seen with vandetanib, serum electrolytes and ECGs should be carefully monitored in patients with diarrhea.

Hypothyroidism

In the randomized MTC study where 90% of the patients enrolled had prior thyroidectomy; increases in the dose of the thyroid replacement therapy were required in 49% of the patients randomized to vandetanib compared to 17% of the patients randomized to placebo. Thyroid-stimulating hormone (TSH) should be obtained at baseline, at 2 to 4 weeks and 8 to 12 weeks after starting treatment with Vandetanib and every 3 months thereafter. If signs or symptoms of hypothyroidism occur, thyroid hormone levels should be examined and thyroid replacement therapy should be adjusted accordingly.

Reversible posterior leukoencephalopathy syndrome (RPLS)

RPLS is a syndrome of subcortical vasogenic edema and it is diagnosed by an MRI of the brain, which has been observed with Vandetanib. This syndrome may occur in any person along with seizures, headache, visual disturbances, confusion or altered mental function. In clinical studies, three of four patients have been found to develop RPLS while taking Vandetanib.

Dosage and administration

Vandetanib may be taken with or without food. It is administered orally and the recommended dose is 300 mg daily. The treatment should be continued with vandetanib until patients are no longer benefiting from treatment or an unacceptable toxicity occurs.

Storage, supplied and handling

The tablets should be stored at temperature of 25°C. Procedures for proper handling and disposal of anticancer drugs should be considered. The various dosage tablets (100 mg, 300mg) should be supplied in bottles and each bottles containing 30 tablets [20].

Drug interactions

Strong CYP3A4 inducers

The drugs includes dexamethasone, phenytoin, carbamazepine, rifampin, rifabutin, rifapentine, Phenobarbital etc are strong CYP3A4 inducers. The patients should not use these strong CYP3A4 inducers during the treatment with vandetanib drug [28].

CYP3A4 inhibitors

Itraconazole is a potent CYP3A4 inhibitor. In healthy subjects, no clinically significant interaction was shown between caprelsa and itraconazole [28, 29].

Drugs that prolong the QT interval

The administration of caprelsa with agents that may prolong the QT interval should be avoided. These drugs are procainamide, sotalol, amiodarone etc [32].

Cost

Vandetanib is estimated to cost \$198 per 100-mg tablet, which at a daily dose of 300 mg equals \$17,820 for a 30-day supply. [33]

Special populations with special care

Pregnancy

When vandetanib is administered to rats at the dose of 300 mg/day, it shows embryotoxicity, fetotoxicity and teratogenicity. When vandetanib is administered to the pregnant woman, it may cause fetal harm. Woman of childbearing potential must use effective contraception during therapy and for at least four months at this dose [20].

Nursing mothers

There are no data on the use of vandetanib in breast-feeding women. Vandetanib and/or its metabolites is excreted into milk in rats and found in plasma of pups following dosing to lactating rats. Breast-feeding is contraindicated while receiving vandetanib therapy [20].

CONCLUSIONS

In April 2011, vandetanib was approved by the US Food and Drug Administration (FDA). It is still under review in Europe and Canada. It is used for the treatment of medullary thyroid cancer (MTC) patients. Vandetanib has now become the new standard of care for patients with unresectable or metastatic MTC in the United States. Further studies are required to define whether vandetanib might play a role in the management of these malignancies.

REFERENCES

1. Bennedbaek FN, Perrild H, Hegedüs L. Diagnosis and treatment of the solitary thyroid nodule. Results of a European survey. *Clin. Endocrinol. (Oxf)* 1999; 50 (3): 357-63.
2. Nix P, Nicolaidis A, Coatesworth AP. Thyroid cancer review 2: management of differentiated thyroid cancers. *Int. J. Clin. Pract* 2005; 59 (12): 1459-63.
3. Ball DW, Baylin SB, Buströs AC. Medullary thyroid carcinoma. In: Werner and Ingbar's the Thyroid, 8th edn. (eds L. E. Braverman & R. E. Utiger), Lippincott Williams & Wilkins, Philadelphia. 2000. p. 930-943.
4. Chong GC, Beahrs OH, Sizemore GW, et al. Medullary carcinoma of the thyroid gland. *Cancer* 1975; 35:695-704.
5. Fragu P. Calcitonin's fantastic voyage: from hormone to marker of a genetic disorder. *Gesnerus* 2007; 64 (1-2): 69-92.
6. Kouvaraki MA, Shapiro SE, Perrier ND, et al. RET proto-oncogene: a review and update of genotype-phenotype correlations in hereditary medullary thyroid cancer and associated endocrine tumors. *Thyroid* 2005; 15(6):531-544.
7. Block MA, Jackson CE, Greenawald KA, et al. Clinical characteristics distinguishing hereditary from sporadic medullary thyroid carcinoma. *Arch Surg* 1980; 115:142-148.
8. Davies L, Welch HG. Increasing incidence of thyroid cancer in the United States, 1973-2002. *JAMA*. 2006; 295(18):2164-7.
9. Enewold L, Zhu K, Ron E, Marrogi AJ, Stojadinovic A, Peoples GE, et al. Rising thyroid cancer incidence in the United States by demographic and tumor characteristics, 1980-2005. *Cancer Epidemiol Biomarkers Prev* 2009;18(3):784-91.
10. Roman S, Lin R, Sosa JA. Prognosis of medullary thyroid carcinoma: demographic, clinical, and pathologic predictors of survival in 1252 cases. *Cancer* 2006; 107(9):2134-2142.
11. Hernandez BY. Thyroid Cancer: Rising Incidence and Ethnic Disparities Hawai'i journal of medicine & public health, august 2012; 71(8).
12. Ohta S, Cho Y, Hiroshi K. Unresectable colorectal cancer cases receiving no-dose-reduction folfiri therapy with the regular administration of granulocyte colony-stimulating factor support: case report with review of literature. *Int J Phar Pharm Sci* 2012; 4(1): 53-55.
13. Pal DK, Saha S, Singh S. Importance of pyrazole moiety in the field of cancer. *Int J Phar Pharm Sci* 2012; 4(2): 98-104.
14. Brierley J, Tsang R, Simpson WJ, Gospodarowicz M, Sutcliffe S, Panzarella T. Medullary thyroid cancer: analyses of survival and prognostic factors and the role of radiation therapy in local control. *Thyroid* 1996; 6 (4): 305-10.
15. Negri E, Ron E, Franceschi S, La Vecchia C, Preston-Martin S, Kolonel L, et al. Risk factors for medullary thyroid carcinoma: a pooled analysis. *Cancer Causes Control* 2002; 13(4):365-72.

16. Thyroid Cancer - American Cancer Society www.cancer.org/thyroid-cancer-pdf
17. Deshpande H, Roman S, Thumar J, et al. Vandetanib (ZD6474) in the treatment of medullary thyroid cancer. *Clin Med Insights Oncol* 2011; 5:213-221.
18. CAPRELSA® (vandetanib) tablets prescribing information. AstraZeneca Pharmaceuticals LP. Available at <http://www1.astrazeneca-us.com/pi/caprelsa.pdf>. Accessed December 14, 2011.
19. Wells SA, Gosnell JE, Gagel RF, et al. Vandetanib for the treatment of patients with locally advanced or metastatic hereditary medullary thyroid cancer. *J Clin Oncol* 2010; 28:767-772.
20. Food and Drug Administration. Vandetanib Package inserts Prescribing information. Reference ID: 2928974-Accessdata FDA- Food and Drug Administration. www.accessdata.fda.gov/drugsatfda_docs/label/.../022405s000lbl.pdf. Accessed 2011.
21. Rodríguez-Antona C, Pallares J, Montero-Conde C, et al. Overexpression and activation of EGFR and VEGFR2 in medullary thyroid carcinomas is related to metastasis. *Endocr Relat Cancer* 2010; 17(1):7-16.
22. Kim ES, Khuri FR, Herbst RS. Epidermal growth factor receptor biology. *Curr Opin Oncol*. 2001; 13(6):506-13.
23. Phay JE, Shah MH. Targeting RET receptor tyrosine kinase activation in cancer. *Clin Cancer Res* 2010; 16(24):5936-5941.
24. Vitagliano D, De Falco V, Tamburrino A, et al. The tyrosine kinase inhibitor ZD6474 blocks proliferation of RET mutant medullary thyroid carcinomacells. *Endocr Relat Cancer* 2010; 18(1):1-11.
25. Sharma SV, Bell DW, Settleman J, Haber DA. Epidermal growth factor receptor mutations in lung cancer. *Nat Rev Cancer* 2007; 7(3):169-81.
26. Lee DH, Lee GK, Kong SY, et al. Epidermal growth factor receptor status in anaplastic thyroid carcinoma. *J Clin Pathol* 2007; 60(8):881-4.
27. Martin, P, Oliver S, Kennedy SJ, Partridge E, et al. Pharmacokinetics of Vandetanib: Three Phase I Studies in Healthy Subjects. *Clinical Therapeutics* 2012; 34 (1): 221-237.
28. Martin P, Oliver S, Robertson J, Kennedy SJ, Read J, Duvauchelle T. Pharmacokinetic drug interactions with vandetanib during coadministration with rifampicin or itraconazole. *Drugs R D* 2011; 11(1):37-51.
29. Wells SA, Robinson BG, Gagel RF, et al. Vandetanib in patients with locally advanced or metastatic medullary thyroid cancer: a randomized, double-blind phase III trial. *J Clin Oncol*. 2012; 30(2):134-41.
30. Rosen AC, Wu S, Damse A, Sherman E, Lacouture ME. Risk of rash in cancer patients treated with vandetanib: systematic review and meta-analysis. *J Clin Endocrinol Metab* 2012; 97(4):1125-33.
31. Yoon J, Oh CW, Kim CY. Stevens - Johnson syndrome induced by vandetanib. *Ann Dermatol* 2011; 23(Suppl 3):S343-5.
32. Zang J, Wu S, Tang L, et al. Incidence and risk of QTc interval prolongation among cancer patients treated with vandetanib: a systematic review and meta-analysis. *PLoS One* 2012; 7(2): e30353.
33. Stenger M. Vandetanib: New Drug for Unresectable Medullary Thyroid Cancer. 2012; 3(8). The ASCO Post. www.ascopost.com/.../vandetanib-new-drug-for-unresectable-medullary.