

Original Article

TOXICITY ASSESSMENT OF *OXALIS CORNICULATA* AND *PHYLLANTHUS FRATERNUS* PLANTS

SANDEEP KUMAR SINGH, VEERU PRAKASH

Department of Biochemistry & Biochemical Engineering, Sam Higginbottom Institute of Agriculture, Technology and Sciences, Allahabad - 211007, Uttar Pradesh, India, Department of Biochemistry & Biochemical Engineering, Sam Higginbottom Institute of Agriculture, Technology and Sciences, Allahabad - 211007, Uttar Pradesh, India

Email: sandeepbiochem83@gmail.com, veeru\_prakash@yahoo.co.in

Received: 26 Feb. 2014 Revised and Accepted: 11 Mar 2014: ??

ABSTRACT

**Objective:** The aim of the present study was to evaluate the LD<sub>50</sub> and hepatorenal toxicity of the ethanolic extracts of common weed plants; *Oxalis corniculata* L. and *Phyllanthus fraternus* L. which are used as traditional therapeutics due to their vast medicinal values.

**Methods:** LD<sub>50</sub> value was determined by feeding CF strain male albino rats with the single oral dose of *O. corniculata* and *P. fraternus* extracts ranging from 200 to 2000 mg/kg body weight (BW). Hepatorenal toxicity was analysed by assay of functional markers of liver and kidney of rats as well as their histopathological studies by supplying single dose of 400 mg/kg BW of above plants extract on daily basis for 7 days and signs of toxicity like inappetence, depression, aggressiveness, body weight loss and respiratory distress to death were observed.

**Results:** In the toxicity test, the LD<sub>50</sub> values were obtained as 1300 mg/kg BW and 1125 mg/kg BW respectively for *Oxalis corniculata* and *Phyllanthus fraternus* ethanolic extract. Albino rats in the study did not express any positive sign of toxicity. Even, rats did not show significant ( $p > 0.05$ ) changes in GOT, GPT, ALP, Urea, Uric acid and Creatinine level in plasma and also no gross changes were observed in anatomy of liver and kidney of treated rats on compare to control rats at the selected dose of 400 mg/kg BW.

**Conclusion:** It is therefore concluded that the dose below LD<sub>50</sub> value of ethanolic extracts of *Oxalis corniculata* and *Phyllanthus fraternus* may safely be used for therapeutic purposes.

**Keywords:** *Oxalis corniculata*, *Phyllanthus fraternus*, LD<sub>50</sub>, Hepatorenal toxicity, Ethanolic extract, Histopathological study, CF strain male albino rats.

INTRODUCTION

Several medicinal plants have been used as dietary adjunct and in the treatment of numerous diseases without proper knowledge of their function and toxicity. According to the World Health Organization about 80% of the world's population living in developing countries relies essentially on plants for primary health care so herbal medicine associated pharmacology and pharmaceutical products are required to update frequently [1, 2]. Research carried out in last few decades has validated several such claims of use of traditional medicinal plants. But without the proper information about efficacy and safety of these traditional medicines sometimes it would be harmful. Common weed plants such as *Oxalis corniculata* L. of Oxalidaceae family and *Phyllanthus fraternus* L. of Euphorbiaceae family are used as traditional therapeutics due to their vast medicinal values. Both plants are good source of vitamin C and used as antiscorbutic in the treatment of scurvy. *O. corniculata* (commonly called as creeping wood sorrel) extract is applied in case of scorpion sting and on skin to treat eczema [3]. It was reported that the aqueous extract of whole plant can eliminate the evil wetness, urethritis, and neurasthenic, injuries from falls, skin ulcer, foot ringworm, eczema, scald, and ringworm on feet [4]. Its ethanolic extract shows significant antitumor and antibacterial activities [5], while methanolic extract display antioxidant and anti-inflammatory activities [6]. *Phyllanthus fraternus* (commonly called as Bhumyamlaiki) is widely utilized against jaundice, alcohol-induced liver damage, kidney stones, hypertension, genito-urinary tract infection, abdominal pain [7]. It was also set up to be helpful in carminative, cooling and overcoming of thirst, bronchitis, asthma, leprosy, anaemia, venereal diseases, problems of the genito-urinary tract, anuria, biliousness and hiccups [8].

*P. fraternus* is also reported to possess antidiabetic [9], antiviral [10], anti-inflammatory [11], analgesic [12], antioxidative and anticoagulant properties [13].

Since various pharmacological studies of both plants were done earlier, the toxicity profile, especially of their ethanolic extracts, has not been yet explored. The present investigation is therefore carried out to study the lethal toxicity and hepatorenal toxicity of ethanolic extract of *Oxalis corniculata* and *Phyllanthus fraternus* plants.

MATERIALS AND METHODS

Plants material

The whole plant of *Oxalis corniculata* and *Phyllanthus fraternus* were collected from Allahabad district, UP, India and authenticated by an Agronomist, Department of Agronomy, SHIATS, Allahabad. A voucher specimen (2011/09/26) has been kept in our laboratory for future reference.

Preparation of ethanolic extract

The fresh whole plant materials were dried in shade at room temperature (28 °C) for 2 weeks, after which these were grinded to a uniform powder. Ethanolic extracts were prepared by soaking 50 g each of the dry powdered plant materials in 600 mL of 95% ethanol at room temperature for 48 h with occasional shaking at every 8 h. It was then filtered by Whatmann filter paper (size no.1) and the filtrates were evaporated on rotary evaporator to concentrate in crude extract form at 40 °C. There, 6.56 g light green residue (13.12% w/w) of *O. corniculata* and 6.50 g dark green residue (13% w/w) of *P. fraternus* were obtained. The aqueous suspensions of these extracts were made by dissolving them into distilled water according to dose values.

Animals

Charles Foster strain male albino rats weighing 200 ± 20 g were used in the study and maintained on standard pellet diet and water *ad libitum*. Rats were acclimatized under standard rat house conditions for 21 days before the trial was initiated. The

temperature of housing environment was maintained at  $25 \pm 2$  °C. The study was approved by the Institutional Animal Ethics Committee (No. IAEC/MCS/2011/12/03).

### Experimental design

Experimental rats were divided into 6 groups (4 rats in each group). In order to select optimum dose of ethanolic extract of *O. corniculata* and *P. fraternus*, graded doses of these extracts were designed as 200, 400, 800, 1200, 1600 and 2000 mg/kg body weight (BW) and evaluated percentage of mortality and LD<sub>50</sub>. Lethal dose study [14] was carried out after 72 hours by oral feeding of these doses to the rats of all groups.

Further, two doses as 200 and 400 mg/kg BW/day of both plant extracts were selected and supplied to healthy male rats for 7 days to check out any sign of behavioural toxicity while normal control rats received similar extent of distilled water. In addition, hepatotoxicity and renotoxicity of rats treated with 400mg/kg BW dose of extracts also checked out by assessing of hepatorenal functional markers and histopathological observations against normal control.

### Biochemical analysis

The impacts of ethanolic extract of *O. corniculata* and *P. fraternus* on liver and kidney function markers were evaluated by estimation of Glutamate Oxaloacetate Transaminase (GOT) [15], Glutamate Pyruvate Transaminase (GPT) [15], Alkaline phosphatase (ALP) [16], Urea [17], Uric acid [18] and Creatinine [19] levels in plasma

samples of normal control and plants extracts treated rats. All analysis was performed by standard enzymatic methods using commercially available kit from CREST BIOSYSTEM LTD.

### Histopathological study

All treated rats with selected dose of ethanolic extract of *O. corniculata* and *P. fraternus* were sacrificed after blood samples collection under guidelines of Institutional Animal Ethical Committee. The tissue samples of liver and kidney were obtained, washed and fixed in 10% neutral formalin and used for histopathological slide preparation as described by Lillie [20]. Slides were observed using X200, X400 objective and results recorded.

### Statistical analysis

All results of liver and kidney function were expressed as mean  $\pm$  SD. Data were analysed by one way ANOVA and followed by Dunnett's multiple comparison test using graph pad prism software (version 5.03) for windows (Graph Pad Software, San Diego, USA).

### RESULTS & DISCUSSION

The death percentage (mortality rate) of rats fed with different doses of ethanolic extract of *Oxalis corniculata* and *Phyllanthus fraternus* were found maximum (100%) at dose of 2000 mg/kg BW, while lowest mortality rate (25%) varied i.e. 800 mg per kg BW for *O. corniculata* and 400 mg per kg BW for *P. fraternus* (Table 1). The 50% lethal dose (LD<sub>50</sub>) values of *O. corniculata* and *P. fraternus* were found @ 1300 mg/kg BW and 1125 mg/kg BW oral respectively (Fig. 1).

Table 1: Percentage mortality of rats receiving different doses of *Oxalis corniculata* and *Phyllanthus fraternus* extract.

Group	No. of Animals	Dose (mg/kg BW)	Dose Diff. (DD)	<i>O. corniculata</i>			<i>P. fraternus</i>		
				Death	Mean Death (MD)	% Mortality	Death	Mean Death (MD)	% Mortality
1	4	200	200	0	0	0	0	0	0
2	4	400	200	0	0	0	1	0.5	25
3	4	800	400	1	0.5	25	1	1.0	25
4	4	1200	400	2	1.5	50	2	1.5	50
5	4	1600	400	2	2	50	3	2.5	75
6	4	2000	400	4	3	100	4	3.5	100

LD<sub>50</sub> = Least dose that killed all animals -  $\Sigma$  (DD x MD) / (No. Animals/group)

Table 2: Toxicity signs in rats at single oral dose of *Oxalis corniculata* and *Phyllanthus fraternus* ethanolic extracts.

Plant extract	Dose (mg/kg BW)	Signs of toxicity					
		Inappetence	Depression	Aggressiveness	Respiratory distress	Body weight loss	Death
<i>Oxalis corniculata</i>	200	Nil	Nil	Nil	Nil	Nil	Nil
	400	Nil	Nil	Nil	Nil	Nil	Nil
<i>Phyllanthus fraternus</i>	200	Nil	Nil	Nil	Nil	Nil	Nil
	400	Nil	Nil	Nil	Nil	Nil	Nil

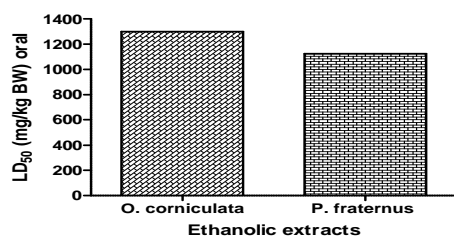


Fig. 1: LD<sub>50</sub> value of *Oxalis corniculata* and *Phyllanthus fraternus* plants.

There were no positive signs of toxicity (such as inappetence, depression, aggressiveness, respiratory distress, body weight loss, death) observed at present doses of 200 and 400 mg/kg BW (Table 2).

Further, results showed a little variations in the values of GOT, GPT, ALP, Urea, Uric acid and Creatinine level in plasma samples of plants extract treated rats at the dose of 400 mg/kg BW, which was found non significant, since p value > 0.05 (Table 3 & 4).

Those GOT and ALP level in plasma of *P. fraternus* extract treated rats were found similar to normal control rats. However *P. fraternus* fed rats displayed comparatively higher GPT level while *O. corniculata* resulted lower than the normal control rats.

The higher GPT level may be due to metabolic oscillation in the rats. Urea level in the plasma was observed decreased while increased in Creatinine with supplement of extracts; *P. fraternus* and *O. corniculata* as compared to normal rats. Although *O. corniculata* extract displayed higher levels of Urea, Uric acid and Creatinine than *P. fraternus* while not much impact on Uric acid level was perceived with the treatment of plant extracts.

Table 3: Hepatic functional markers in plasma of plants extract treated rats at the dose of 400 mg/kg BW.

Biochemical markers (in plasma)	Normal control	Ethanol extract treated	
		<i>O. corniculata</i>	<i>P. fraternus</i>
GPT (U/ml)	72.87 ± 1.44	71.87 ± 0.75*	74.50 ± 1.87*
GOT (U/ml)	86.25 ± 0.72	87.81 ± 1.20*	86.50 ± 0.68*
ALP (KA units/ml)	9.25 ± 0.69	8.74 ± 0.42*	9.75 ± 0.32*

Table 4: Renal functional markers in plasma of plants extract treated rats at the dose of 400 mg/kg BW.

Biochemical markers (in plasma)	Normal control	Ethanol extract treated	
		<i>O. corniculata</i>	<i>P. fraternus</i>
Urea (mg/dl)	33.86 ± 0.67	31.75 ± 1.17*	29.79 ± 2.04**
Uric acid (mg/dl)	6.43 ± 0.38	6.45 ± 0.42*	6.02 ± 0.20*
Creatinine (mg/dl)	1.19 ± 0.24	1.37 ± 0.48*	1.25 ± 0.29*

Values are mean ± SD, R= 4 \*means are significantly not different as p > 0.05 for extract treated vs. normal control; \*\*means are significantly different as p < 0.05 for extract treated vs. normal control.

### Histopathological results

Histological studies of the liver and kidney tissues of both normal control rat as well as extracts treated rats did not exhibited any major or specific anatomical changes (Fig. 2A, 2B, 2C, 3A, 3B & 3C).

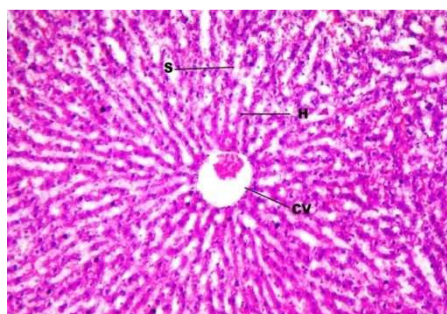


Fig. 2A: Liver of normal control rat (10 × 20 X).

Note: H = hepatocyte, S = sinusoids, CV = central vein

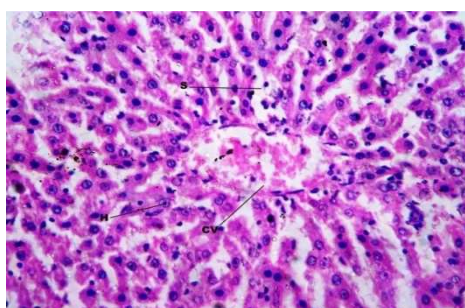
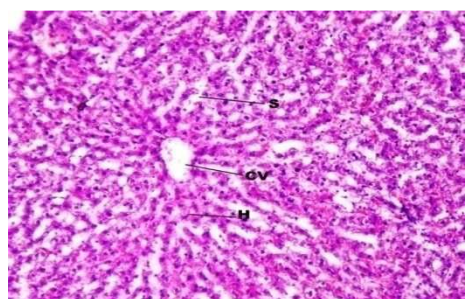
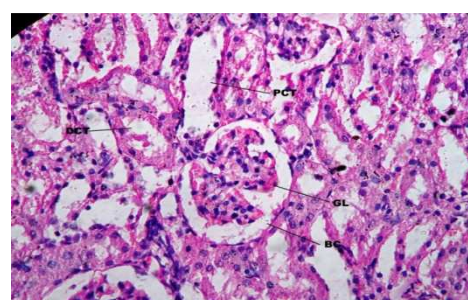
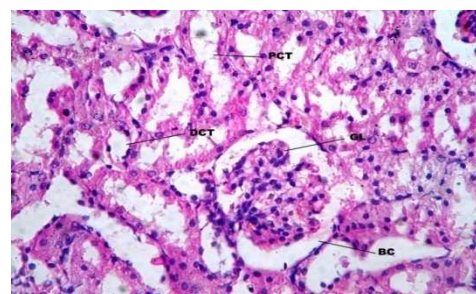
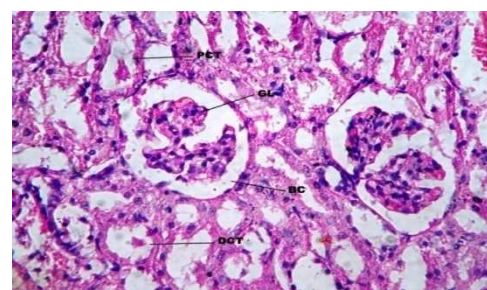
Fig. 2B: Liver of rat treated with *O. Corniculata* extract @ 400 mg/kg BW (10 × 40).Fig. 2C: Liver of rat treated with *P. fraternus* extract @ 400 mg/kg BW (10 × 40 X).

Fig. 3A: Kidney of normal control rat (10 × 40 X).

Note: GL = glomerulus, BC = bowman capsule, PCT = proximal convoluted tubule, DCT = distal convoluted tubule

Fig. 3B: Kidney of rat treated with *O. corniculata* extract @ 400 mg/kg BW (10 × 40 X).Fig. 3C: Kidney of rat treated with *P. fraternus* extract @ 400 mg/kg BW (10 × 40 X).

Medicinal plants and herbal preparations have recently received considerable attention and have been found to be promising choice over modern synthetic medicines [21]. *Oxalis corniculata* and *Phyllanthus fraternus* are also used as traditional

therapeutics due to their vast medicinal values but safety studies at toxicity level are lacking in the literatures. Thus present investigation was aimed to study the lethal dose, hepatotoxicity and renoxicity of ethanolic extract of *Oxalis corniculata* and *Phyllanthus fraternus*. The observed values in toxicological studies of *O. corniculata* and *P. fraternus* plants ethanolic extracts exhibited low toxicities and almost certainly safe uses as traditional healers. LD<sub>50</sub> value gives a satisfactory dose model to any drug design, so commonly used for assay of lethal toxicity of herbal preparation. The LD<sub>50</sub> values of *O. corniculata* and *P. fraternus* were found as 1300 mg/kg BW and 1125 mg/kg BW oral respectively and almost no mortalities in rats up to dose of 400 mg/kg. In addition, flavonoids, carotenoids, phenols, non protein thiols and ascorbic acid compounds were observed in extracts of both plants [22]. According to the toxicity scale of Hodge and Sterner any compound with an oral LD<sub>50</sub> of between 500-1000 mg/kg should be considered practically non toxic [23, 24]. At present in the context of recommendation of OECD (Organisation for Economic Co-operation and Development) for chemical labelling and classification of acute systemic toxicity based on oral LD<sub>50</sub> values, the extract/compound are considered as: very toxic, < 5 mg/kg body weight; toxic, > 5 < 50 mg/kg; harmful, > 50 < 500 mg/kg; and no label, > 500 < 2000 mg/kg BW [25]. Earlier, no report on lethal dose of *O. corniculata* and *P. fraternus* ethanolic extract was reported. Kalyani et al. [26] in their study found no mortality up to dose 2000 mg/kg BW of methanolic extract of *P. fraternus*. Experimentally, plants treated rats did not show any positive sign of inappetence, depression, aggressiveness, body weight loss and respiratory distress to death over to control rats @ 200 and 400 mg/kg BW that reveal its safe oral dose for therapeutical uses. Creatinine, urea and uric acid are markers of kidney function [27]. Elevation of these markers may indicate renal damage. In present study, both plants extracts treated rats did not show any significant difference ( $p > 0.05$ ) in renal function markers against the normal control group except the slight decrease in urea level of *P. fraternus* treated rats at the dose of 400 mg/kg BW, which might be due to excess excretion of urine prior to sample collection or might be due to low protein diet. It can be also supported by gross anatomical observation of renal tissues, which showed no cellular changes over the control rats (Fig. 3A, 3B & 3C). Previous studies reported that the rise in the plasma GOT, GPT and ALP enzymes activity is often observed as a consequence of hepatocellular damage [28, 29 & 30]. Further, it can be noticed that there was not too much difference in plasma GOT, GPT and ALP enzymes activity of *O. corniculata* and *P. fraternus* treated rats compared to the control group ( $p > 0.05$ ) and was not even observed in hepatocellular studies of both treated and control rats (Fig. 2A, 2B & 2C).

## CONCLUSION

It is therefore concluded that the dose below LD<sub>50</sub> value of ethanolic extracts of *Oxalis corniculata* and *Phyllanthus fraternus* may safely be used for medicinal purposes. The extracts reveal no significant negative effect on hepatorenal parameters tested against animal model. Findings justify the therapeutic use of these plants in folk medicine. There still remains the need for elucidating the molecular structures and the precise pharmacology of the active principles.

## ACKNOWLEDGEMENT

The authors are also thankful to Hon'ble Vice-Chancellor, Sam Higginbottom Institute of Agriculture, Technology and Sciences, Allahabad for providing all necessary facilities and Dr. Arun Kumar, Research department, Mahavir Cancer Sansthan, Patna, Bihar, India for their guidance in carrying out animal work.

## REFERENCES

- McKay DL, Blumberg JB. A review of the bioactivity of South African herbal teas: Rooibos (*Aspalathus linearis*) and Honey comb (*Cyclopia intermedia*). *Phytother Res* 2007; 21: 01.
- Wang ZG, Ren J. Current status and future direction of Chinese herbal Medicine. *Trends in Pharma Sci* 2002; 23: 347.
- Kathiriya AK, Das K, Joshipura M, Mandal N. *Oxalis corniculata* Linn.; The plant of Indian subtropics. *Herbal Tech Industry* 2010; August: 07.
- Sumei L, Chuein L, Fengyan L, Sangwoo L, Qi G, Rong L et al. Herbs for medicinal baths among the transitional Yao communities of China. *J Ethnopharmacol* 2006; 108: 59.
- Raghvendra MP, Satish S, Raveesha KA. Phytochemical analysis and antibacterial activity of *Oxalis Corniculata*: a known medicinal plant. *my SCIENCE* 2006; 1: 72.
- Sakat SS, Juvekar AR, Gambhire MN. *In vitro* antioxidant and anti inflammatory activity of methanol extract of *Oxalis corniculata* L. *Int J Pharm Pharm Sci* 2010; 2(1): 146.
- STEPRI, CSIR. *Phyllanthus*. In: K. Busia, editor. *Ghana Herbal Pharmacopoeia*. 2<sup>nd</sup> ed. STEPRI, Accra, 2007. p. 198.
- Oudhia P. *Phyllanthus fraternus* GL Webster. In: Schmelzer GH, Gurib-Fakim A, editors. *Medicinal plants/Plantes médicinales*. Protologue: 11(1), *Contr Gray Herb*, 2008. p. 53.
- Kushwah AS, Patil BM, Thippeswami BS. Effect of *Phyllanthus fraternus* on fructose induced insulin resistance in rats. *Int J Pharmacol* 2010; 6: 624.
- Ogata T, Higuchi H, Mochida S, Matsumoto H, Kato A. HIV-1 reverse transcriptase inhibitor from *Phyllanthus niruri*. *AIDS Res Hum Retroviruses* 1992; 8: 19-37.
- Calixto JB, Santos AR, Filho VC, Yunes RA. A review of the plants of the genus *Phyllanthus*: Their chemistry, pharmacology and therapeutic potential. *Med Res Rev* 1998; 18: 225.
- Santos AR, Filho VC, Niero R, Viana AM, Moreno FN. Analgesic effects of callus extracts from selected species of *Phyllanthus* in mice. *J Pharm Pharmacol* 1994; 46: 755.
- Koffuor GA, Amoateng P. Antioxidant and Anticoagulant Properties of *Phyllanthus fraternus* GL Webster (Family: Euphorbiaceae). *J Pharmacol Toxicol* 2011; 6: 624.
- Aliu YO, Nwude N. In: *Veterinary Pharmacology and Toxicology Experiments*, 1<sup>st</sup> ed. ABU Press, 1982. p. 104.
- Reitman S, Frankel S. Determination of aspartat and alanine aminotransferase in blood serum and tissue homogenate. *Amer J Clin Pathol* 1957; 28: 56.
- Kind PRN, King EJ. Estimation of Plasma Phosphatase by Determination of Hydrolysed Phenol with Amino-antipyrine. *J Clin Pathol* 1954; 7(4): 322.
- Fawcett JK, Scott JE. A rapid and precise method for the determination of urea. *J Clin Pathol* 1960; 13(2): 156.
- Fossati P, Prencipe L, Berti G. Use of 3, 5-Dichloro- 2-hydroxybenzenesulfonic Acid/4-Amino nophenazone Chromogenic System in Direct Enzymic Assay of Uric Acid in Serum and Urine. *Clin Chem* 1980; 26(2): 227.
- Bonsnes RW, Taussky HH. On the colorimetric determination of Creatinine by the Jaffe reaction. *J Biol Chem* 1954; 158: 581.
- Lillie RD. *Histopathological technique and practical histochemistry*. 3<sup>rd</sup> ed. 10-New York, Toronto, London: Blakistar Division of Mc. Graw Hill Publishers; 1965.
- Saha P, Mazumder UK, Haldar PK. Acute and Subchronic Toxicity of *C. maxima* Aerial Parts. *Int J Res Pharma Biomed Sci* 2011; 2(2): 634.
- Singh SK, Prakash V. Screening of antioxidant activity and phytochemicals strength of some herbal plants. *Int J Pharm Pharm Sci* 2013; 5(3): 296-300.
- Hodge HC, Sterner HJ. Acute toxicity determination. *Amer Indust Hygien Assoc* 1943; 10: 93.
- Agaie BM, Onyeyili PA, Muhammad BY, Ladan MJ. Acute toxicity effects of the aqueous leaf extract of *Anogeissus leiocarpus* in rats. *Afr J Biotech* 2007; 6(7): 886.
- Walum E. Acute oral toxicity. *Environ Health Perspect* 1998; 106(2): 497.
- Kalyani B, Khavane K, Payghan S, Setty Ramchandra S. Evaluation of Diuretic Activity of *Phyllanthus fraternus* Web Aerial Parts on Albino Rats. *Int J Pharma Biol Arch* 2010; 1(4): 389-392.
- Newman DJ, Price CP. Renal function and nitrogen metabolites. In: Burtis CA, Ashwood ER, editors. *Tietz textbook of Clinical Chemistry*. Philadelphia: WB Saunders Company Publishers; 1999. p. 1204 - 1270.
- Tilkian SM. *Clinical Implications of Laboratory Test*. Nissouri: The CV Mosby Company Publishers; 1979. p. 11-17.

29. Dial JM. Clinicopathological evaluation of the liver. *Vet Clin* 1995; 25: 275-293.
30. Woodman DD. Study of serum toxicity. *J Applied Toxicol* 1988; 84: 249-254.